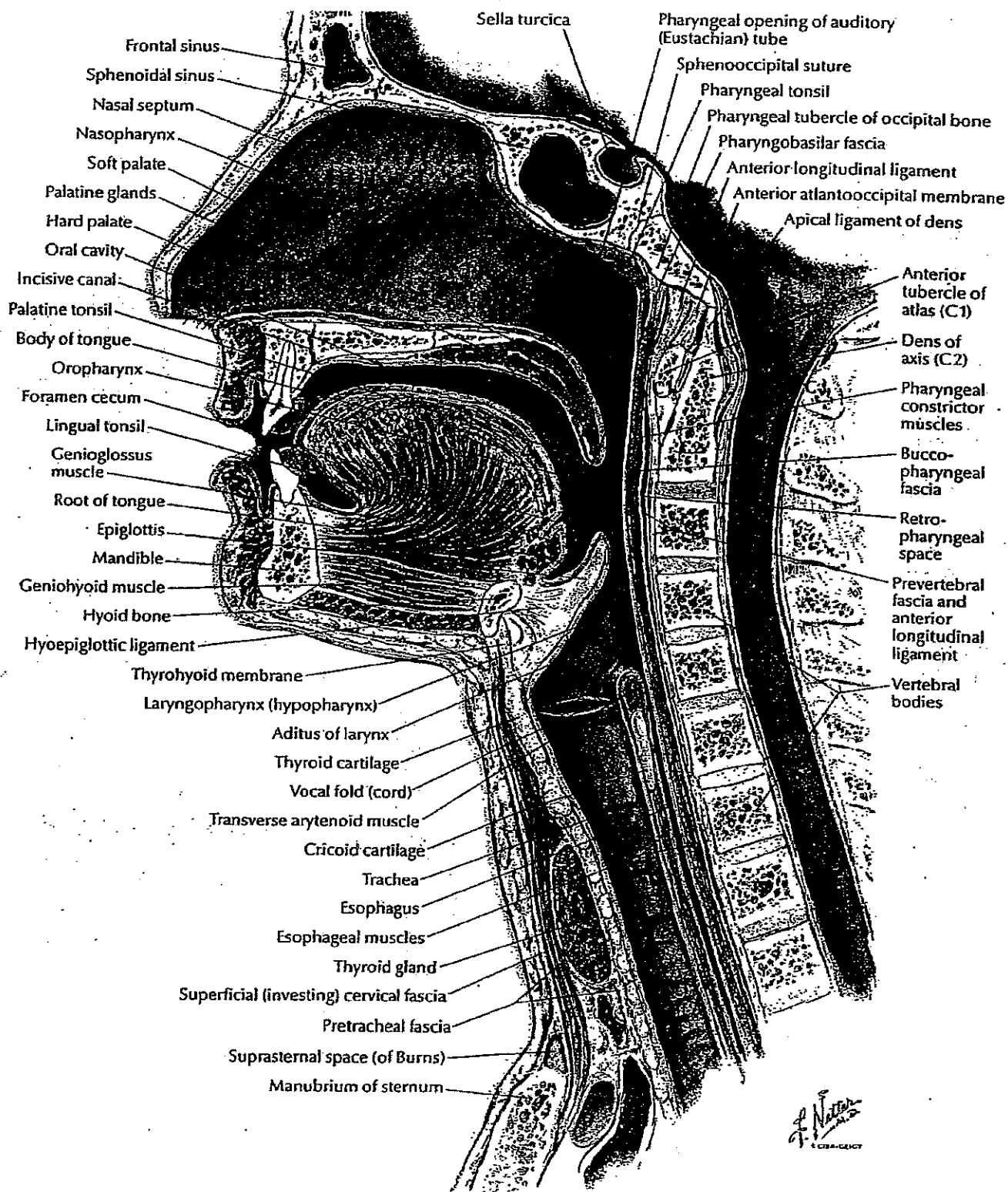


# Pharynx: Sagittal Section



*A. Netter*  
M.D.